Human Genetics
https://doi.org/10.1007/s00439-023-02527-3

ORIGINAL INVESTIGATION

PRSS8, encoding prostasin, is mutated in patients with autosomal recessive ichthyosis

Hanan E. Shamseldin[1] · Nada Derar[2] · Hamad Alzaidan[2] · Naif AlHathal[3] · Abdullah Alfalah[2] · Firdous Abdulwahab[1] · Tariq Alzaid[5] · Salim Alkeraye[4] · Saud A. Alobaida[6] · Fowzan S. Alkuraya[1,7]

Received: 30 September 2022 / Accepted: 20 January 2023

Abstract

Ichthyosis is a genetically heterogeneous genodermatosis characterized by severely rough, dry and scaly skin. We report two consanguineous families with congenital ichthyosis. Combined positional mapping and exome sequencing of the two families revealed novel homozygous likely deleterious variants in *PRSS8* (encoding prostasin) within a linkage locus on chromosome 16. One variant involved a canonical splice site and was associated with reduced abundance of the normal transcript, while the other was a missense variant that altered a highly conserved residue. The phenotype of *Prss8* knockout mouse bears a striking resemblance to the one we describe in human patients, including the skin histopathology. Our data suggest a novel *PRSS8*-related ichthyosis disorder.

Introduction

Ichthyosis is a Mendelian group of epidermis cornification disorders that manifest clinically as scaling (hence the Greek root "ichthys", which means fish), hyperkeratosis, erythroderma, palmoplantar keratoderma and hyperlinearity (Fischer and Bourrat 2020). The most common forms of ichthyosis are the autosomal dominant filaggrin (FLG)-related ichthyosis vulgaris and X-linked recessive steroid sulfatase (STS)-related ichthyosis (Oji et al. 2010). In inbred populations, however, autosomal recessive forms represent a substantial fraction of congenital ichthyosis with an expansive list of genes that underlie both syndromic and non-syndromic subtypes (Fischer and Bourrat 2020).

Proteases have been known to play a key role in regulating the dynamic nature of the skin epidermis, which is characterized by a balance between new keratinocyte formation at the basal layer and their desquamation at the stratum corneum layer. Accordingly, pathogenic variants in genes encoding various proteases have been found to cause ichthyosis. Examples include autosomal recessive ichthyosis with hypotrichosis caused by mutation of *ST14*, encoding type II transmembrane serine protease matriptase (Basel-Vanagaite et al. 2007), autosomal recessive exfoliative ichthyosis caused by mutation of *CSTA*, encoding the protease Cystatin A (Blaydon et al. 2011), and autosomal dominant ichthyosis caused by mutation of *ASPRV1*, encoding a mammalian-specific and stratified epithelia-specific protease important in processing filaggrin (Boyden et al. 2020). Interestingly, the pathogenesis of *ABCA12*-related autosomal recessive ichthyosis has also been attributed to impaired processing of epidermal proteases (Thomas et al. 2009).

GPI-anchored channel-activating protease gene (*CAP1*, also known as protease serine S1 family member 8 [*PRSS8*]), encodes prostasin, a highly conserved

✉ Fowzan S. Alkuraya
falkuraya@kfshrc.edu.sa

1 Department of Translational Genomics, Center for Genomic Medicine, King Faisal Specialist Hospital and Research Center, Riyadh, Saudi Arabia

2 Department of Medical Genomics, Center for Genomic Medicine, King Faisal Specialist Hospital and Research Center, Riyadh, Saudi Arabia

3 Department of Urology, King Faisal Specialist Hospital and Research Center, Riyadh, Saudi Arabia

4 Department of Dermatology, King Khalid University Hospital and College of Medicine, King Saud University, Riyadh, Saudi Arabia

5 Department of Pathology and Laboratory Medicine, King Faisal Specialist Hospital and Research Center, Riyadh, Saudi Arabia

6 Department of Dermatology, King Faisal Specialist Hospital and Research Center, Riyadh, Saudi Arabia

7 Department of Anatomy and Cell Biology, College of Medicine, Alfaisal University, Riyadh, Saudi Arabia

Published online: 30 January 2023

mammalian protein expressed in semen, prostate gland and skin (Vuagniaux et al. 2000). Based on the remarkable resemblance of the skin phenotype of *Prss8* knockout mouse to other mouse models of human ichthyosis, it has been proposed as a compelling candidate gene (Leyvraz et al. 2005). However, there has been no report to date of *PRSS8* being mutated in patients with ichthyosis. Here, we report two families that support the existence of a human *PRSS8*-related ichthyosis.

Materials and methods

Human subjects

Patients, siblings and parents from two unrelated families were recruited after obtaining informed consent under an IRB-approved research protocol (KFSRHC RAC# 2121053). Clinical details were provided by their treating physicians. Blood samples were collected in EDTA tubes for DNA extraction. A skin biopsy was obtained with informed consent from the index patient in Family A.

Autozygome mapping and exome sequencing

DNA samples from all family members were submitted for genomewide SNP genotyping using Axiom SNP Chip platform following the manufacturer's instructions. AutoSNPa software (http://dna-leeds.co.uk/autosnpa/) was used for analysis of genotyping data and identification of homozygosity loci shared by affected members. Given the parental consanguinity, regions of homozygosity > 2 Mb were considered as surrogates of autozygosity. Linkage analysis was used to confirm the candidate autozygome and calculate LOD score based on a fully penetrant autosomal recessive model using the EasyLINKAGE package. Exome sequencing (ES) was performed using an Agilent Sureselect All Exons V5 (50 Mb) capture kit (Agilent Technologies; Santa Clara, CA, USA) for library preparation. Briefly, DNA was sheared mechanically after which targeted fragments were captured by probe hybridization and amplified before sequencing. An Illumina HiSeq 2500 (Illumina Inc; San Diego, CA, USA) was used for paired-end 100nt sequencing. Sequence alignment, indexing of the reference genome (hg19), variant calling and annotation used a pipeline based on BWA, Samtools, GATK (https://software.broadinstitute.org/gatk/) and ANNOVAR, respectively. One index from each family was submitted for ES, and the resulting variants were filtered with focus on homozygous coding/splicing variant within the candidate autozygome, absent or very rare in Saudi and public exome databases and predicted to be pathogenic by SIFT, PolyPhen, CADD, and Trap scores, as applicable.

Cell culture

Control and affected fibroblasts cell lines were propagated in Minimum Essential Media (MEM) (Thermo Fisher Scientific) supplemented with 15% v/v fetal bovine serum (Thermo Fisher Scientific, #16140071), 1% v/v L-glutamine, and 1% v/v penicillin and streptomycin and incubated in a humidified 5% CO_2 atmosphere at 37 ºC. Cells were harvested following 75–80% confluence using trypsin–EDTA detachment (0.05% trypsin, 2 mM EDTA).

Quantitative reverse transcription polymerase chain reaction (qRT-PCR)

RNA was extracted from control and index fibroblasts with Qiagen RNeasy kit, according to the manufacturer's protocol. cDNA was synthesized with Super Script IV VILO system (Invitrogen). qPCR was performed using SYBR Green reagent (Qiagen) reaction on Step-One Plus Real PCR system (Applied Biosystems). All analyses were performed with delta CT quantitation and normalization to *GUSB* as internal control, and *t*-test was used for *P* value calculation.

In silico modeling

Pymol was used to show the position of the mutated residue withing the trypsin domain and another tool (http://missense3d.bc.ic.ac.uk/missense3d) was used for the prediction of its effect.

Results

Clinical report

Family A comprises three affected sons with congenital ichthyosis born to consanguineous parents. The index IV:1 (21DG0457) is a 37-year-old male presented with diffuse xerosis and fine white scales, more obvious on the extremities with larger scales that are attached centrally with an outward turning edge. Sparing of the folds was also noticed. Nails, palms, and soles were normal. Microscopy of the hair did not reveal any abnormality in the hair shaft. Hematoxylin and Eosin (H&E) staining of skin section revealed compact hyperkeratosis and parakeratosis, with preserved Stratum granulosum (Fig. 1C–G). This individual also had a left ectopic kidney, which appeared relatively smaller compared with the normally located right kidney, measuring 9.5 cm,

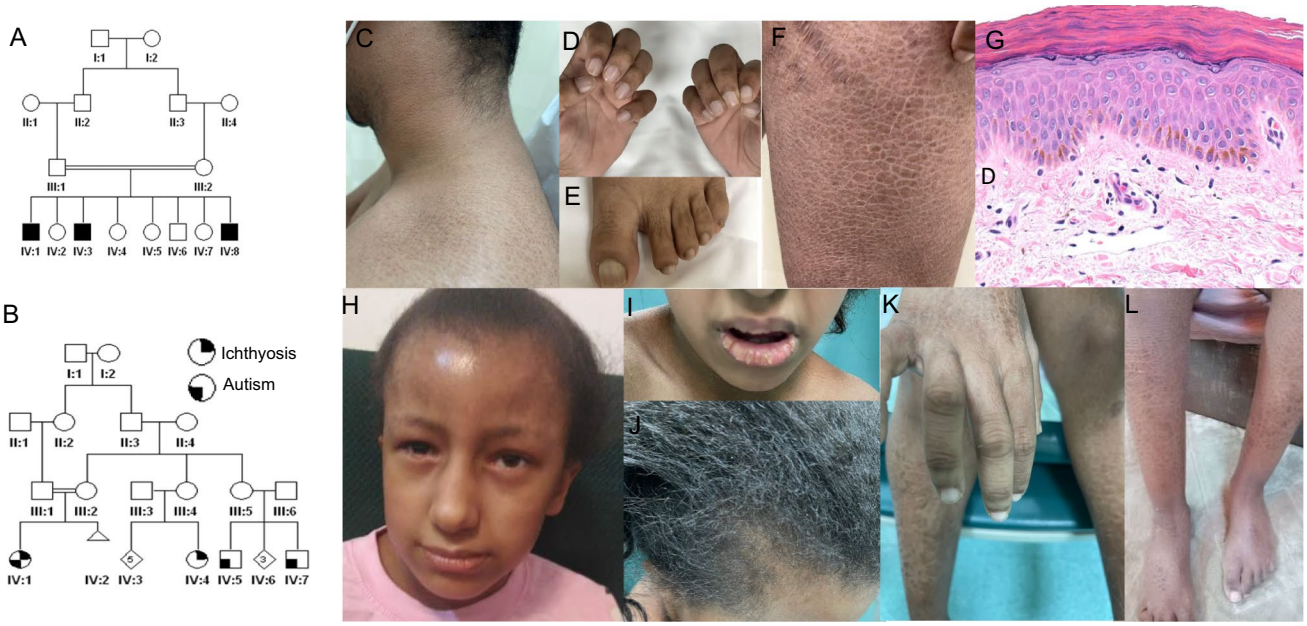

Fig. 1 **A**, **B** Pedigrees of the families A and B. Symbols denote different phenotypes observed in family A. **C–F** Clinical images of family A_IV:1 showing dry scaly skin, sparing of the fold in the neck. **G** H&E histopathology of the skin showing hyperkeratosis, parakeratosis and preserved stratum granulosum. **H–L** Clinical images of family B_IV:1 showing dry scaly skin, stomatitis and brittle hair (pictures were taken at different time points)

compared to 11.9 cm, with mild parenchymal irregularity, and nonspecific 0.5 cm echogenicity within the lower pole of the kidney. The left renal pelvis measured 1.2 cm in diameter with persistent moderate hydronephrosis. The urinary bladder appeared unremarkable, without evidence of masses or stones. Furthermore, there is history of left ureteropelvic junction (UPJ) obstruction diagnosed by cystoscopy and left retrograde pyelography and treated with stent insertion. Abdominal CT scan showed horizontally oriented ectopic left kidney within the center of the pelvis against the sacral promontory, with persistent fetal lobulation, but no evidence of masses or stones. There is mild to moderate pelvicalyceal dilatation. The renal pelvis was observed anterior in location, while the renal pelvis funnel was oriented towards the left iliac fossa. DMSA scan showed normal function of both kidneys. The two affected brothers (1 V:3, age 34 years and IV:8, age 16 years) had an identical dermatological phenotype (Table S1) but lacked the urological phenotype.

Family B is also consanguineous. The only affected member (IV:1, 21DG0892) is a 9-year-old girl with autism and congenital ichthyosis. She was referred to clinical genetics because of severe skin dryness and scaliness with associated developmental delay. Skin examination revealed severe generalized ichthyosis that is more pronounced over the upper and lower extremities. The lips showed significant stomatitis. Palms and soles were normal and there was no nail involvement. Hair examination showed woolly appearance and temporal recession. There was no mucosal involvement (Fig. 1H–L). Her renal ultrasound showed normal kidneys with no mass lesion, stones or hydronephrosis. The right kidney measured 8.7 cm and the left 8.3 cm, both normal in size. One of her cousins (IV:4) presented the same skin phenotype but without autism while two other cousins (IV:5 and IV:7) had autism but normal skin (none of these relatives agreed to be evaluated or recruited for sampling), suggesting two distinct phenotypes within the family.

A novel form of congenital ichthyosis maps to *PRSS8*

Due to the consanguineous nature of the pedigrees, we ran combined linkage analysis of the two families, and adopted homozygosity mapping-guided exome filtering to identify homozygous, novel coding or canonical splicing variant within the candidate homozygous locus. Indeed, a single linkage peak with a LOD score of 3.8 was observed in chromosome 16 delimited by rs205381 and rs882353 (chr16: 28,038,778–49,737,067) (Fig. 2A). In Family A, the three affected members shared a homozygous region on chromosome 16 within which exome revealed a homozygous canonical splicing variant in *PRSS8*: NM_002773:c.706-1G>A (Fig. 2B, C), which fully segregated with the phenotype under the autosomal recessive model (Figs. 2B and S-1A). The variant was absent in gnomAD, and 12,435 local exomes so it met the ACMG criteria for PVS1, PM2 and PP1. On RT-PCR using fibroblast-derived RNA, no aberrant splicing was detected but quantitative RT-PCR

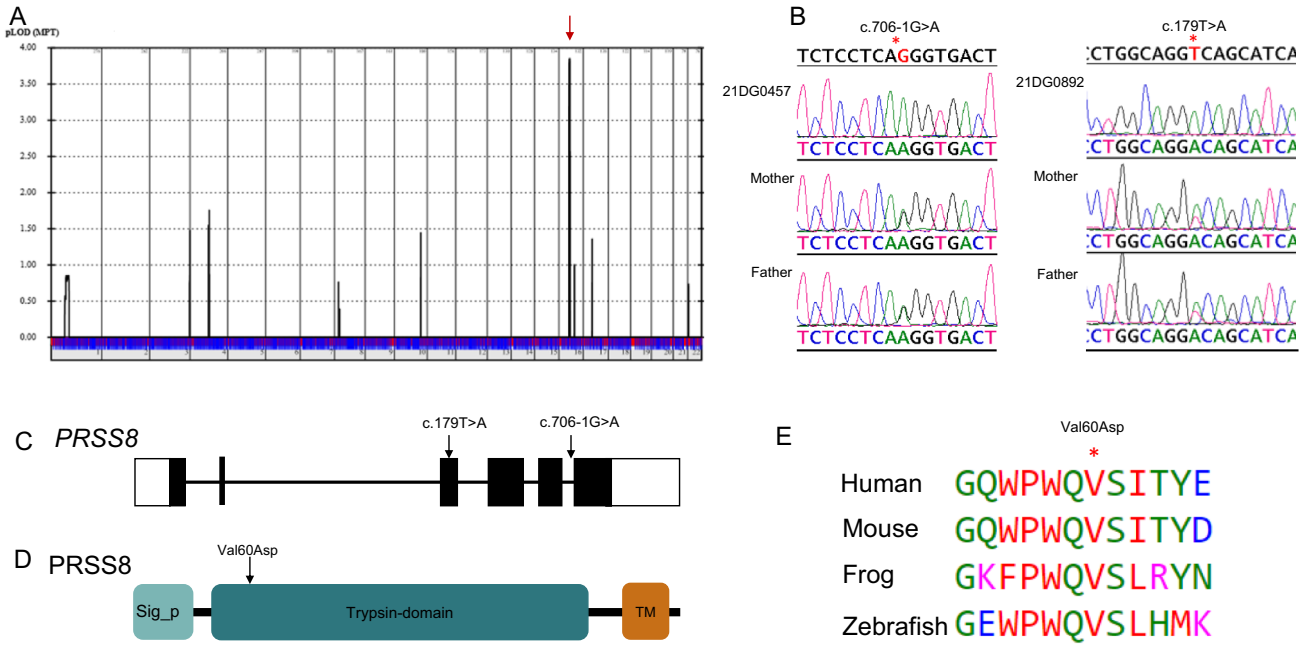

Fig. 2 **A** Genomewide linkage analysis of both families revealing a locus on chromosome 16 with LOD score of 3.8. **B** Sequence chromatogram of the *PRSS8* variants: NM_002773:c.706-1G>A, and NM_002773:c.179T>A:p.(Val60Asp) for index patients and parents. **C** Schematic of *PRSS8* gene with arrows indicating position of the two variants. **D** Schematic of PRSS8 protein. **E** Conservation of Val60 across species

revealed significant reduction in the normal *PRSS8* transcript ($p = 0.004$, Fig. S2).

ES of the index patient in family-B revealed two candidate variants namely, *PRSS8*: NM_002773:c.179T>A:p.(Val60Asp), and *TAAR1*: NM_138327:c.787T>C:p.(Cys263Arg). However, only the *PRSS8* variant was within the candidate locus. It changes a highly conserved hydrophobic N-terminal Valine to Aspartic acid with a strong deleterious in silico prediction (SIFT = 0.0, PolyPhen = 1, CADD = 29) (Fig. 2B–E). The variant is absent in local and gnomAD databases so it met the ACMG criteria for PM2, PP1 and PP3. Using ClinGen framework for scoring novel gene–disease assertions, *PRSS8*-related ichthyosis assertion scores 8 based on human and mouse data and qualifies as "moderate". The *TAAR1*variant has similarly strong deleterious in silico prediction (SIFT = 0.001, PolyPhen = 1 and CADD = 25) and was absent in local and gnomAD databases so it qualifies for PM2 and PP3. No human diseases have been associated with *TAAR1* and we could not pursue its potential role in autism through segregation because the extended family members declined participation. Thus, *TAAR1*-related autism assertion scores only 3 on the ClinGen score sheet and qualifies as "limited". Detailed segregation results are shown in Figure S2. No rare surviving variant was identified in known ichthyosis genes in either of the two families' exomes (Table S2).

Valine 60 is located within the highly conserved trypsin domain, the active site domain of serine proteases which is composed of two antiparallel beta barrels. This valine is completely buried in the interior of the protein with RSA of 0.7% (cutoff for defining a residue as buried is < 9.0%). The substitution Val60Asp introduces a hydrophilic negatively charged residue in the core of the protein (Fig. S4) which might affect its stability, as hydrophobic interaction plays a role in regulating zymogen activation of trypsin (Ittisoponpisan et al. 2019; Hedstrom et al. 1996). Of note, proteins with trypsin domain as an active site belong to Serine peptidase-1 family [Table S1 shows a partial representative list of trypsin family in eukaryotes based on http://www.ebi.ac.uk/interpro/entry/InterPro/IPR001254/ (Rawlings and Barrett 1994)]. Aligning prostasin to these protein sequences revealed that mutated Valine 60 is either conserved as valine or is replaced by the alternative hydrophobic residue Alanine (Fig. S4).

Discussion

As expected in a highly consanguineous population, autosomal recessive forms of ichthyosis are overrepresented in our study population. In a large exome-first study involving > 2200 families with various Mendelian phenotypes, *TGM1*-related and *CYP4F22*-related congenital ichthyosis were the most common forms (Monies et al. 2019). In addition, we have previously identified novel syndromic

and non-syndromic forms of ichthyosis including *ELOVL4*-related Sjogren–Larssen syndrome, *PHGDH*-related Neu–Laxova syndrome, *AP1B1*-related MEDNIK-like syndrome and *UGCG*-related ichthyosis (Aldahmesh et al. 2011; Shaheen et al. 2014; Alsaif et al. 2019; Monies et al. 2018). In our cohort of 17 families with autosomal recessive congenital ichthyosis, the two families described here are the only remaining families that did not map to a known ichthyosis-related gene. Indeed, our results suggest that the phenotype seen in these two families represents a novel autosomal recessive form of congenital ichthyosis caused by *PRSS8* deficiency.

Prostasin is also known as channel-activating protease (CAP)-1, which activates the epithelial sodium channel (ENaC). Several mouse models strongly implicate *PRSS8* in the etiology of congenital ichthyosis. The oldest known mouse model is *frizzy* in 1951 that was found in 2010 to be caused by a spontaneous V170D substitution (Spacek et al. 2010). The same investigators went on to show that the *hairless* rat was similarly caused by an in-frame 12 bp deletion in the rat ortholog of *PRSS8* (Spacek et al. 2010). Another point variant (S238A) was found to abrogate the catalytic activity of PRSS8 and when introduced in a mouse line resulted in a dramatic skin phenotype similar to *frizzy* (Peters et al. 2014). What these mice have in common is highly abnormal epidermis with impaired barrier function leading to highly penetrant pre-weaning lethality due to abnormal water loss. Specifically, *Prss8* knockout mice displayed distortion of the stratum corneum and its lipid composition, defective processing of profilaggrin, immature and reduced number of hair follicles, and absence of tight junction protein (occludin), resulting in impaired skin barrier function, dehydration, and death within 60 h after birth (Leyvraz et al. 2005). Another catalytically dead mutant (R44Q) that is resistant to actives site cleavage, resulted in one chain zymogen instead of two chains of active prostasin. This mutant showed normal epidermal barrier function and postnatal development but presented kinky and curly whiskers with delayed eruption, and sparse pelage hair (Friis et al. 2016). Thus, *Friis* et al. concluded that prostasin has dual in vivo functions: the enzymatically inactive prostasin is involved in interfollicular epidermal development while the active form is involved in hair follicle development. In this regard, individual 21DG0457 with compact hyperkeratosis and parakeratosis relatively mimics the histology of *PRSS8* -/- knockout mouse which in addition to hyperkeratosis presented reduced hair follicles. Due to the presence of normal hair shaft in this individual we speculate that mutated *PRSS8* in this individual might affect the non-enzymatic interfollicular epidermis function of prostasin proposed by Peters et al. (2014), Friis et al. (2016). This is challenged, however, by the clinical observation in 21DG0892 whose woolly hair appearance seems to be similar to the curly vibrissae frizzy mouse (Spacek et al. 2010; Friis et al. 2016) and mouse with defective hair, whisker and pelage hair, which lacks enzymatic activity of prostasin (Friis et al. 2016). Thus, one might argue that both functions of prostasin are affected by the other variant.

The autism phenotype in the index patient in family-B is hard to reconcile with the observation of three affected siblings in family A with no developmental concerns. We suggest that this may be a hybrid phenotype related to an independent variant, which is strongly supported by the observation that autism and ichthyosis segregate independently within the family. In this regard, the *TAAR1* variant is an attractive candidate. *TAAR1* encodes a trace amine-associated receptor 1, a G protein-coupled receptor widely expressed in the brain, and is activated by amino acid metabolites with a suggested role of maintaining the neuronal activity of monoamine neurotransmitters (Berry 2007). *Taar1* homozygous knockout mice display abnormal learning behavior (Espinoza et al. 2015). To date, no human disease has been linked to variants in *TAAR1,* so we acknowledge the need for more patients to determine if the cognitive phenotype in our patient is related to the *TAAR1* variant.

In conclusion, we propose a novel autosomal recessive ichthyosis caused by *PRSS8* deficiency with a strong support from several mouse lines.

Supplementary Information The online version contains supplementary material available at https://doi.org/10.1007/s00439-023-02527-3.

Acknowledgements We thank the patients and their families for their enthusiastic participation.

Author contributions The referring physicians (ND, HA, NA, AA, SA and SA) performed the clinical investigation and provided clinical information, and relevant clinical images. The anatomical pathologist (TA) provided histopathological insight into the disease mechanism and comparison to the published mouse histopathology. Material preparation, data collection and analysis were performed by (HES and FA). FSA and all authors contributed to writing of the manuscript, and the final version was read and approved by all authors. Study Supervision: FSA.

Funding The authors have not disclosed any funding.

Data availability The datasets generated during and/or analysed during the current study are available from the corresponding author on reasonable request.

Declarations

Conflict of interest On behalf of all authors, the corresponding author states that there is no conflict of interest.

Ethics approval This study was approved by King Faisal Specialist Hospital and Research Center—Research Ethics committee. The research conformed to the principles of the Helsinki Declaration. This study was performed in line with the principles of IRB-approved research protocol (KFSRHC RAC# 2121053).

Consent to participate Informed consent was obtained from all individual participants included in the study."

"Written informed consent was obtained from the parents.

Consent to publish The authors affirm that human research participants provided informed consent for publication of the images in Fig. 1(C-I).

References

Aldahmesh MA, Mohamed JY, Alkuraya HS et al (2011) Recessive mutations in ELOVL4 cause ichthyosis, intellectual disability, and spastic quadriplegia. Am J Hum Genet 89(6):745–750

Alsaif HS, Al-Owain M, Barrios-Llerena ME et al (2019) Homozygous loss-of-function mutations in AP1B1, encoding beta-1 subunit of adaptor-related protein complex 1, cause MEDNIK-like syndrome. Am J Hum Genet 105(5):1016–1022

Basel-Vanagaite L, Attia R, Ishida-Yamamoto A et al (2007) Autosomal recessive ichthyosis with hypotrichosis caused by a mutation in ST14, encoding type II transmembrane serine protease matriptase. Am J Hum Genet 80(3):467–477

Berry M (2007) The potential of trace amines and their receptors for treating neurological and psychiatric diseases. Rev Recent Clin Trials 2(1):3–19

Blaydon DC, Nitoiu D, Eckl K-M et al (2011) Mutations in CSTA, encoding Cystatin A, underlie exfoliative ichthyosis and reveal a role for this protease inhibitor in cell-cell adhesion. Am J Hum Genet 89(4):564–571

Boyden LM, Zhou J, Hu R et al (2020) Mutations in ASPRV1 cause dominantly inherited ichthyosis. Am J Hum Genet 107(1):158–163

Espinoza S, Lignani G, Caffino L et al (2015) TAAR1 modulates cortical glutamate NMDA receptor function. Neuropsychopharmacology 40(9):2217–2227

Fischer J, Bourrat E (2020) Genetics of inherited ichthyoses and related diseases. Acta Derm Venereol 100(7):186–196

Friis S, Madsen DH, Bugge TH (2016) Distinct developmental functions of prostasin (CAP1/PRSS8) zymogen and activated prostasin. J Biol Chem 291(6):2577–2582

Hedstrom L, Lin T-Y, Fast W (1996) Hydrophobic interactions control zymogen activation in the trypsin family of serine proteases. Biochemistry 35(14):4515–4523

Ittisoponpisan S, Islam SA, Khanna T, Alhuzimi E, David A, Sternberg MJ (2019) Can predicted protein 3D structures provide reliable insights into whether missense variants are disease associated? J Mol Biol 431(11):2197–2212

Leyvraz C, Charles R-P, Rubera I et al (2005) The epidermal barrier function is dependent on the serine protease CAP1/Prss8. J Cell Biol 170(3):487–496

Monies D, Anabrees J, Ibrahim N et al (2018) Identification of a novel lethal form of autosomal recessive ichthyosis caused by UDP-glucose ceramide glucosyltransferase deficiency. Clin Genet 93(6):1252–1253

Monies D, Abouelhoda M, Assoum M et al (2019) Lessons learned from large-scale, first-tier clinical exome sequencing in a highly consanguineous population. Am J Hum Genet 104(6):1182–1201

Oji V, Tadini G, Akiyama M et al (2010) Revised nomenclature and classification of inherited ichthyoses: results of the First Ichthyosis Consensus Conference in Sorèze 2009. J Am Acad Dermatol 63(4):607–641

Peters DE, Szabo R, Friis S et al (2014) The membrane-anchored serine protease prostasin (CAP1/PRSS8) supports epidermal development and postnatal homeostasis independent of its enzymatic activity. J Biol Chem 289(21):14740–14749

Rawlings ND, Barrett AJ (1994) Families of serine peptidases. Methods Enzymol 244:19–61. https://doi.org/10.1016/0076-6879(94)44004-2

Shaheen R, Rahbeeni Z, Alhashem A et al (2014) Neu-Laxova syndrome, an inborn error of serine metabolism, is caused by mutations in PHGDH. Am J Hum Genet 94(6):898–904

Spacek DV, Perez AF, Ferranti KM et al (2010) The mouse frizzy (fr) and rat 'hairless'(frCR) mutations are natural variants of protease serine S1 family member 8 (Prss8). Exp Dermatol 19(6):527–532

Thomas AC, Tattersall D, Norgett EE, O'Toole EA, Kelsell DP (2009) Premature terminal differentiation and a reduction in specific proteases associated with loss of ABCA12 in Harlequin ichthyosis. Am J Pathol 174(3):970–978

Vuagniaux G, Vallet V, Jaeger NF et al (2000) Activation of the amiloride-sensitive epithelial sodium channel by the serine protease mCAP1 expressed in a mouse cortical collecting duct cell line. J Am Soc Nephrol 11(5):828–834