Laryngoscope 97: August 1987

SINONASAL UNDIFFERENTIATED CARCINOMA: A DISTINCTIVE AND HIGHLY AGGRESSIVE NEOPLASM*†

PAUL A. LEVINE, MD
HENRY F. FRIERSON, JR., MD
STACEY E. MILLS, MD
F. MARC STEWART, MD
ROBERT E. FECHNER, MD
ROBERT W. CANTRELL, MD
Charlottesville, VA

ABSTRACT

Eleven cases of sinonasal undifferentiated carcinoma were treated between 1975 and 1986. This distinctive neoplasm involved the orbital cavity in 6 of 11 patients (55%) and the cranial cavity in 7 of 11 patients (64%) at the time of presentation. Of the eight patients (73%) who died of disease, six died within 13 months after the diagnosis. One patient has no evidence of disease 10 months after therapy, and two are alive with disease after 15 and 22 months.

Poorly differentiated neoplasms of the nose and paranasal sinuses are common, and, because of the histologic similarities of some of the tumors that may arise in this anatomic locus, they are sometimes difficult to diagnose. Microscopically, the differential diagnosis of these neoplasms that are composed of small and medium-sized cells must include melanoma, malignant lymphoma,[1] olfactory neuroblastoma,[2] rhabdomyosarcoma, neuroendocrine carcinoma,[3,4] and lymphoepithelioma. We report 11 cases of undifferentiated carcinoma of the nose and sinuses that are clinically and pathologically distinct from all the above neoplasms. This tumor, designated as sinonasal undifferentiated carcinoma (SNUC), behaves aggressively and results in a poor prognosis.

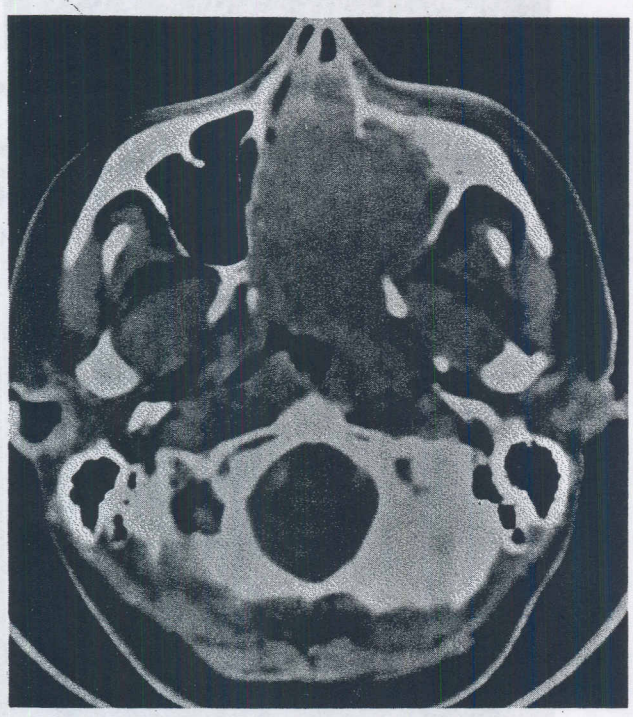

Fig. 1. A high resolution axial CT image showing SNUC involving the entire nasal cavity and left maxillary sinus with erosion of the left medial maxilla, bilateral pterygoid plates, and extension to the left nasopharynx.

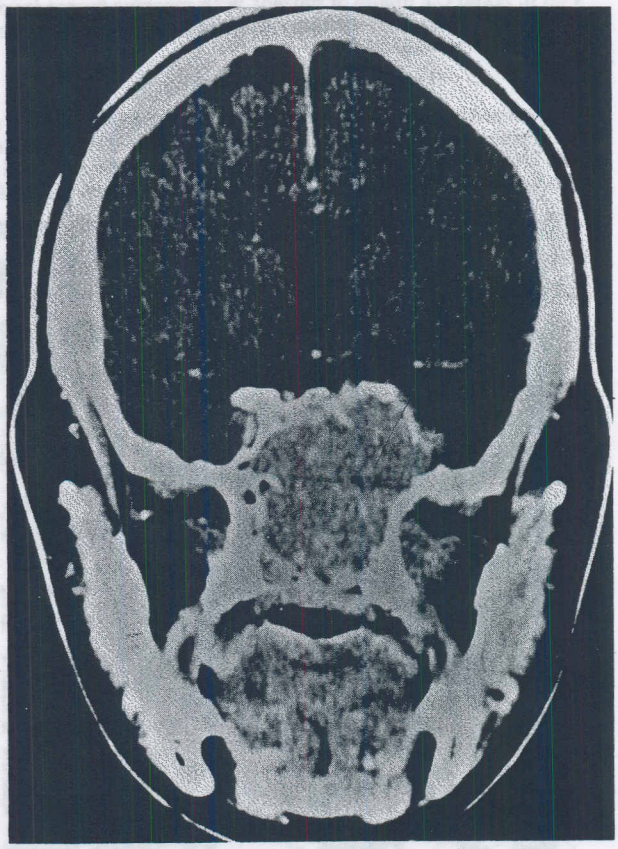

Fig. 2. Coronal image of same patient showing massive tumor involvement of the sphenoid with erosion of the left sphenoid wall and anterior clinoid to involve the left cavernous sinus (arrow).

*Presented at the Meeting of the Southern Section of the American Laryngological, Rhinological and Otological Society, Inc., Santa Fe, NM, January 16, 1987.

†From the Departments of Otolaryngology-Head and Neck Surgery (P.A.L., R.W.C.), Department of Pathology (H.F.F., S.E.M., R.E.F.), and the Division of Hematology-Oncology of the Department of Medicine (F.M.S.), University of Virginia Medical Center, Charlottesville, VA.

Send Reprint Requests to Paul A. Levine, MD, Department of Otolaryngology-Head and Neck Surgery, University of Virginia Medical Center, Box 430, Charlottesville, VA 22908.

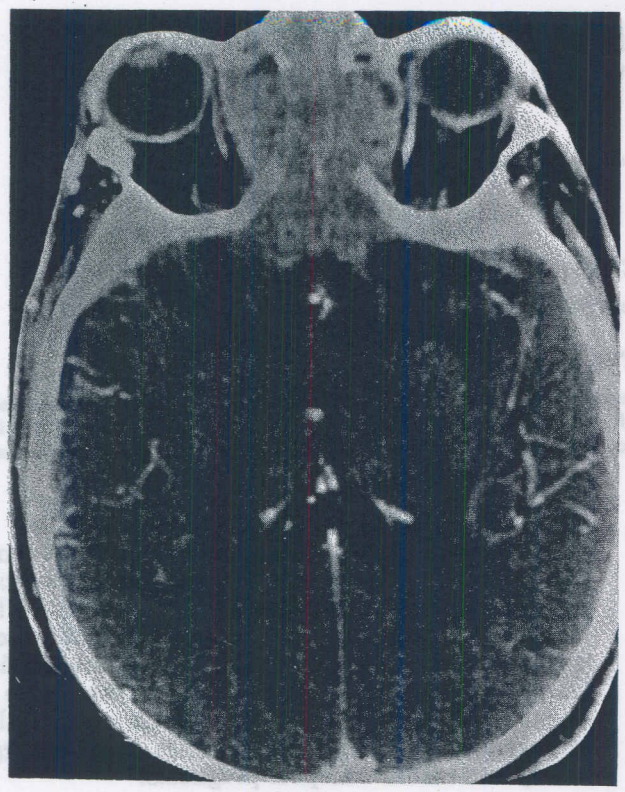

Fig. 3. Axial CT image of patient with massive tumor involvement of both nasoethmoid complexes and extension into the anterior cranial fossa (arrow).

MATERIALS AND METHODS

The records of the Departments of Otolaryngology-Head and Neck Surgery and Pathology and the McIntire Tumor Registry of the University of Virginia Medical Center were reviewed between the years 1942 and 1986. Tissue sections from all cases of the nose and paranasal sinuses diagnosed as lymphoma, esthesioneuroblastoma, and anaplastic or undifferentiated carcinoma were examined. Eleven neoplasms that fulfilled the microscopic criteria for SNUC were identified. The clinical data concerning each case was then reviewed, and follow-up information was obtained.

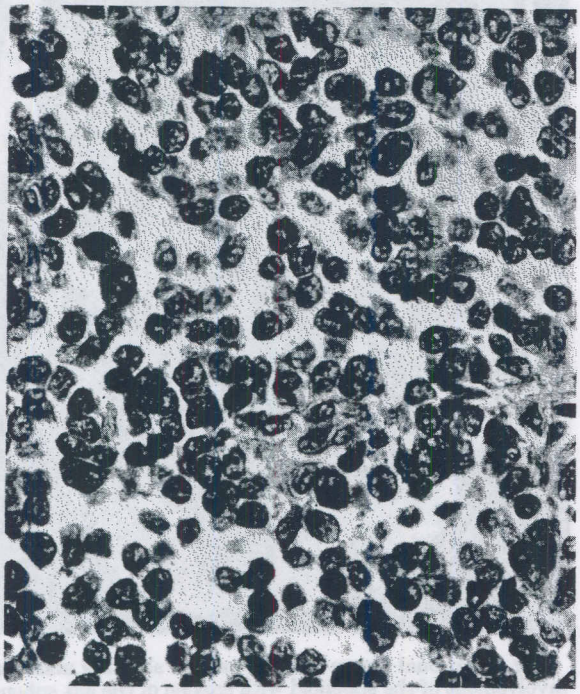

Fig. 4. The bland cytologic features of esthesioneuroblastoma.

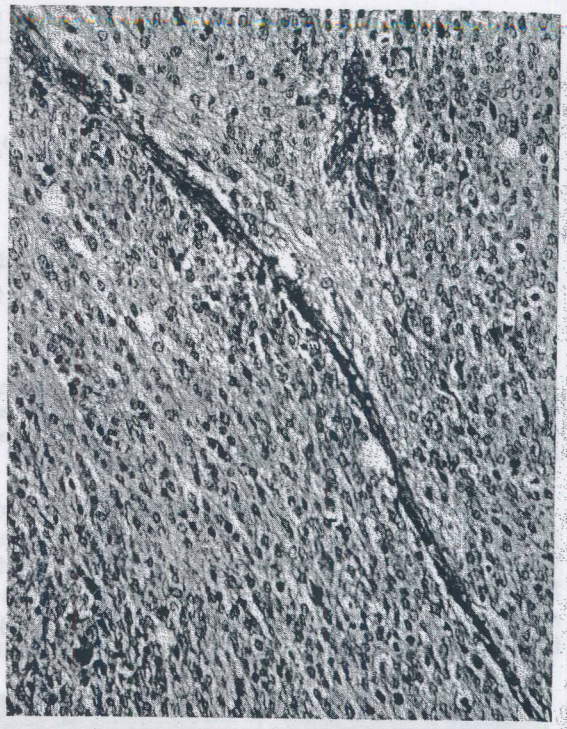

Fig. 5. Cells of esthesioneuroblastoma in a background of intercellular neurofibrils.

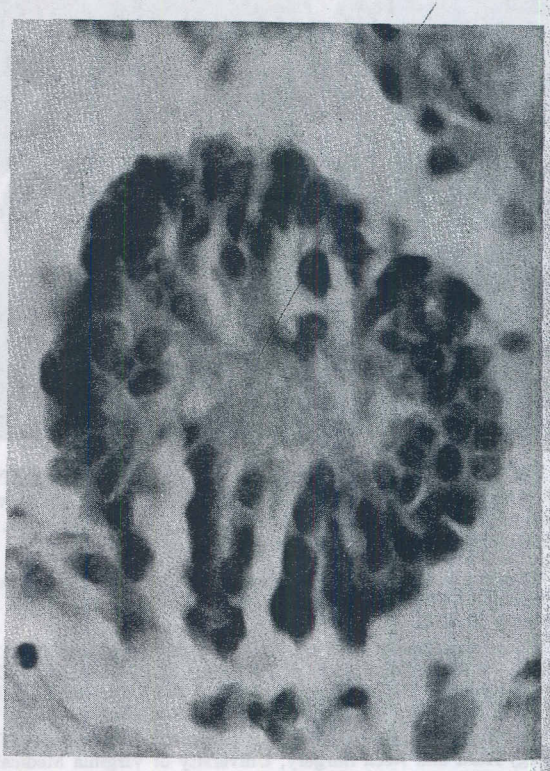

Fig. 6. Cellular formation of the Homer-Wright rosette, diagnostic for esthesioneuroblastoma.

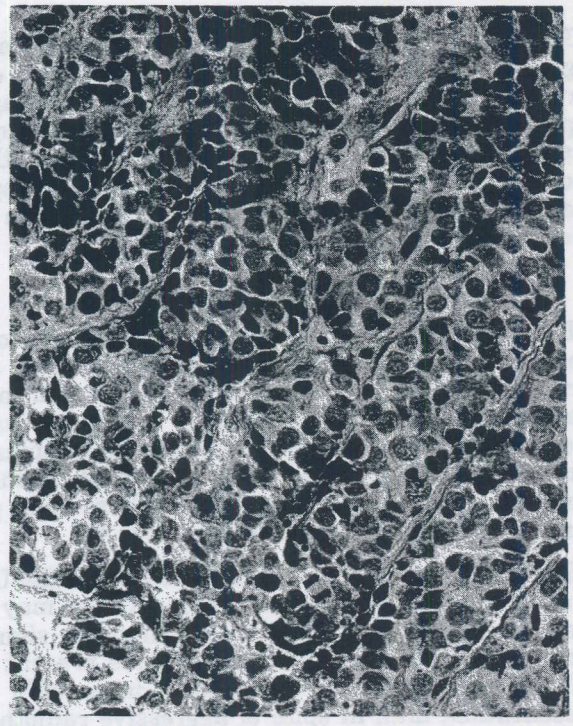

Fig. 7. Medium-sized cells of sinonasal undifferentiated carcinoma (SNUC) arranged in nests, wide trabeculae, and sheets.

CLINICAL FEATURES

Seven patients with SNUC were female and four were male. The ages ranged from 20 to 74 years, with a mean of 49.9 years. The patients lived in a broad geographic region of Virginia and West Virginia, with the exception of one patient referred from Pittsburgh, Pennsylvania. Eight of the 11 patients presented in 1985 or 1986, and 3 were examined between the years 1975 and 1983.

Eight patients had a smoking history. Two patients did not smoke, and one was not able to provide an adequate history secondary to senile dementia. One patient had been exposed to the fumes of sulfuric and chromic acid in conjunction with nickel, copper, and zinc while working in a chrome plating factory. One patient, who presented at the age of 23, had a retinoblastoma at the age of 11 months that was treated with an enucleation, chemotherapy, and radiation therapy. He was free of disease for 22 years.

The most common initial symptoms were facial pain, nasal obstruction, proptosis, and epistaxis. There were also cranial nerve palsies and diplopia. Two patients had a recent onset of impaired mental status, and one presented with a jugulodigastric lymph node without other symptoms.

The most impressive finding in each of the patients was the initial extent of disease, sometimes in patients who had only minimal symptoms, and the rapidity of onset of the symptoms. Figures 1 and 2 exhibit an axial and coronal CT scan from a typical patient. Figure 1 shows a large tumor mass

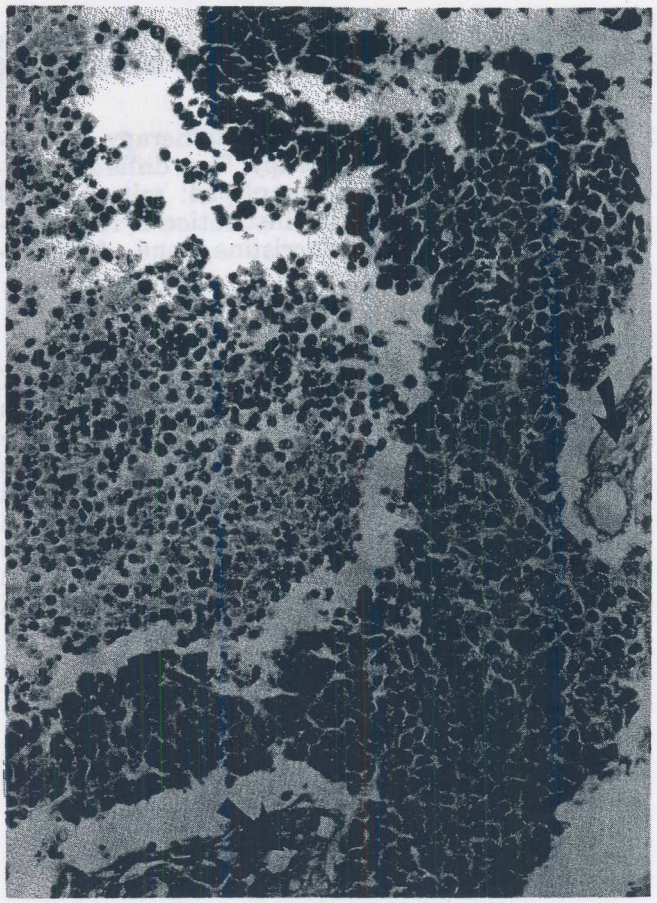

Fig. 8. SNUC showing necrosis and vascular permeation (arrow points to blood vessel wall).

of the entire nasal cavity and left maxillary sinus, with erosion of the medial maxillary wall, septum, and bilateral pterygoid plates, and extending into the left nasopharynx to the prevertebral fascia. The coronal image in Figure 2 shows massive tumor involvement of the sphenoid with erosion of the right lateral sphenoid wall and clinoid to involve the right cavernous sinus. Figure 3 is an axial image of another patient exhibiting massive tumor extension into both nasoethmoid complexes with significant involvement of the anterior cranial fossa.

Virtually all the neoplasms involved the nasal, maxillary, and ethmoid complexes at the time of presentation. Importantly, 6 of the 11 patients presented with orbital involvement and 7 had cranial cavity involvement.

THERAPY

All but one patient was treated with curative doses of radiotherapy, and the majority were treated with chemotherapy. One patient, treated with a craniofacial resection, was referred from Pennsylvania after the initial diagnosis of esthesioneuroblastoma. Patients were treated with radiotherapy varying from 400 rads to 6,000 rads, with the usual dose being between 5,000 and 6,000 rads.

The patient that received only 400 rads died of a brain herniation 2 days after the institution of therapy.

Seven patients received chemotherapy in conjunction with the radiotherapy. Two different regimen combinations were employed: mitomycin C and 5 fluorouracil with the institution of radiotherapy, and Cytoxan®, vincristine, and Adriamycin® prior to radiation therapy.

RESULTS

Eight patients died, and three are alive as of December 1986. One patient is alive at 10 months without evidence of disease. Two patients are alive with disease 15 and 22 months after the completion of therapy. The eight patients who died of the disease had an average survival of 12.4 months after the initial presentation. Two patients died of central nervous system complications early on (meningitis and brain herniation), and six died of extensive local and metastatic disease.

DISCUSSION

While melanoma, lymphoma, rhabdomyosarcoma, and lymphoepithelioma are included in the differential diagnosis of poorly differentiated sinonasal tumors, they can be distinguished by their clinical, light microscopic, and, if necessary, electron microscopic and immunocytochemical features.

The more difficult diagnostic dilemma lies in the differentiation of neuroendocrine carcinoma and esthesioneuroblastoma from SNUC. Silva, *et al.*,[4] described the series of neuroendocrine carcinomas of the nasal cavity in 20 patients who, unlike those with SNUC, had a favorable prognosis with a 100% 5-year survival and a 77% 10-year survival rate. The authors reported that these tumors had a low mitotic rate and only focal necrosis, with little nuclear anaplasia.[4]

The diagnosis of esthesioneuroblastoma by light microscopy is based upon cells having bland nuclear features that lie in a background of intercellular neurofibrils (Figs. 4,5). The Homer-Wright rosette is characteristic of this neoplasm (Fig. 6), but is not necessary for an absolute diagnosis.[5]

The diagnosis of SNUC can usually be made by light microscopy alone. The medium-sized cells are arranged in nests, wide trabeculae, and sheets (Fig. 7). There is usually extensive necrosis and vascular permeation (Fig. 8). SNUC is immunoreactive with antibodies to cytokeratin and, often, to epithelial membrane antigen and neuron-specific enolase.[6]

Because of the difficulty that may occur in making this diagnosis in small, mechanically distorted biopsies, it is imperative that an undamaged representative biopsy be submitted for pathologic examination. For tumors that are necrotic or that show crush artifact, it may be necessary to biopsy the patient more than once in order to obtain an adequate tissue specimen.

CONCLUSIONS

Because SNUC is a rare neoplasm the pathologic features of which have only recently been described in detail,[6] it is possible that similar neoplasms have been encountered by others but have been designated as undifferentiated or anaplastic carcinoma. Eight previously reported tumors may, in fact, be SNUC, since five of these eight patients died within 11 months of diagnosis.[7-10]

Sinonasal undifferentiated carcinoma (SNUC) is a highly aggressive, rare neoplasm that may be present in patients who have symptoms significantly less than the amount of disease present on CT or MRI scans. It is usually inoperable on presentation, and, in spite of aggressive radiotherapy and chemotherapy, results in death within 13 months.

BIBLIOGRAPHY

1. Frierson, H. F., Jr., Mills, S. E. and Innes, D. J., Jr.: Non-Hodgkin's Lymphomas of the Sinonasal Region: Histologic Subtypes and Their Clinicopathologic Features. *Am. J. Clin. Pathol.*, 81:721-727, 1984.

2. Levine, P. A., McLean, W. C. and Cantrell, R. W.: Esthesioneuroblastoma: The University of Virginia Experience. LARYNGOSCOPE, 96:742-746, 1986.

3. Kameya, T., Shimosato, Y., Adachi, I., *et al.*: Neuroendocrine Carcinoma of the Paranasal Sinus. A Morphological and Endocrinological Study. *Cancer*, 45:330-339, 1980.

4. Silva, E. G., Butler, J. J., MacKay, B., *et al.*: Neuroblastomas and Neuroendocrine Carcinomas of the Nasal Cavity. A Proposed New Classification. *Cancer*, 50:2388-2405, 1982.

5. Obert, G. J., Devine, K. D. and McDonald, J. R.: Olfactory Neuroblastoma. *Cancer*, 13:205-215, 1960.

6. Frierson, H. F., Jr., Mills, S. E., Fechner, R. E., *et al.*: Sinonasal Undifferentiated Carcinoma: An Aggressive Neoplasm Derived from Schneiderian Epithelium and Distinct from Olfactory Neuroblastoma. *Am. J. Surg. Pathol.*, 10:771-779, 1986.

7. Koss, L. G., Spiro, R. H. and Hajdu, S.: Small Cell (Oat Cell) Carcinoma of Minor Salivary Gland Origin. *Cancer*, 30:737-741, 1972.

8. Raychowdhuri, R. N.: Oat-Cell Carcinoma and Paranasal Sinuses. *J. Laryngol. Otolaryngol.*, 79:253-255, 1965.

9. Rejowski, J. E., Campanella, R. S. and Block, L. J.: Small Cell Carcinoma of the Nose and Paranasal Sinuses. *Otolaryngol. Head Neck Surg.*, 516-517, 1982.

10. Weiss, M. D., deFries, H. O., Taxy, J. B., *et al.*: Primary Small Cell Carcinoma of the Paranasal Sinuses. *Arch. Otolaryngol.*, 109:341-343, 1983.